



Frequency of Cervicofacial Necrotizing Fasciitis Secondary to Odontogenic Abscess

Juárez-Rebollar Alejandra Giselle^{1*}, López-Saucedo Francisco², Juárez-Rebollar Daniel³ and Juárez-Paredes Celso Marcelo¹

Affiliation

¹Mexican Institute of Social Security (IMSS), Mexico

²Maxillofacial Surgery service, Specialty Hospital "Dr. Antonio Fraga Mouret" La Raza National Medical Center, IMSS, Mexico

³Regional Hospital Lic. Adolfo López Mateos, Mexico

***Corresponding author:** Juárez-Rebollar Alejandra Giselle, PGY4 Maxillofacial Surgery Resident, Specialty Hospital "Dr. Bernardo Sepúlveda Gutiérrez" National Medical Center, XXI Century, IMSS, Cuauhtémoc 330, Doctores, Cuauhtémoc, 06720, Mexico City, Mexico. Tel: 55 5627 6900, E-mail: giselle_juarez@hotmail.com

Citation: Giselle JRA, Francisco LS, Daniel JR and Marcelo JPC. Frequency of cervicofacial necrotizing fasciitis secondary to odontogenic abscess (2020) Dental Res Manag 4: 46-51.

Received: Sep 07, 2020

Accepted: Oct 12, 2020

Published: Oct 17, 2020

Copyright: © 2020 Giselle JRA, et al., This is an open-access article distributed under the terms of the Creative Commons Attribution License, which permits unrestricted use, distribution, and reproduction in any medium, provided the original author and source are credited.

Abstract

Introduction: One of the complications of odontogenic abscess is cervicofacial necrotizing fasciitis; which is infrequent in the cervicofacial region. This disease usually occurs in immunosuppressed patients. Treatment is broad spectrum antibiotics and surgery. **Material and Method:** A research study was conducted with the following characteristics: retrospective, descriptive, cross-sectional and observational, for a year, in the maxillofacial surgery service, of specialty hospital: "Dr. Antonio Fraga Mouret", national medical center "La Raza" (IMSS), Mexico city; all patients (six) diagnosed with necrotizing cervicofacial fasciitis secondary to Odontogenic abscess, older than 18 years were included. The protocol consisted of taking a biopsy, antibiotic, culture with an antibiogram and surgical management. Data were collected to estimate the frequency of this pathology in the maxillofacial surgery service. **Results:** In one year, 6 patients with a diagnosis of necrotizing cervicofacial fasciitis secondary to odontogenic abscess were treated. No significant differences were found with respect to gender, the mean age was 69.16 years, (86; minimum 40). The mean number of affected aponeurotic spaces was 6.5 (maximum: 14; minimum: 2); the most affected side was the right. The most frequent aponeurotic spaces were: the facial (in turn, more were reported in the submandibular followed by submental and genian aponeurotic space) and one third the cervical. Surgical management was: cannulation and drainage of persistent abscess or purulent collection in four patients, surgical lavage was performed in all, 3 patients required more than 4 surgical washes. Debridement was performed in all patients. **Discussion:** The importance of this study is to show and report the frequency with which necrotizing cervicofacial fasciitis appears secondary to odontogenic abscess, to continue with the control and report in maxillofacial surgery, as well as improvements and proposals for a better management of patients who are diagnosed with this disease.

Keywords: Fasciitis, Odontogenic, Abscess, Infection, Cervicofacial.

Introduction

Infections of odontogenic origin can be caused by cavities, pulpitis, periapical abscess, periodontitis, periodontal abscess, and pericoronitis [1]. When odontogenic infections spread through aponeurotic spaces, they form cellulitis or abscess, which if not treated properly, can become complicated and aggravated, compromising the general condition and/or life of the patient. When an odontogenic infection is established in the patient's body and the host's resistance factors are not sufficient to control it, it spreads to adjacent tissues [1,2]. The extension of the infection to these spaces involves factors related to the immune resistance of the host, the virulence of the microorganisms and their invasive capacity. The anatomical sites determine the direction of dissemination of the dental infection is related to the proximity of the apex to the cortex, bone thickness, vestibular depth, muscle attachments and maxillary aponeurosis. They are of typically polybacterial etiology, it is a rare infection of the soft tissues, usually caused by virulent bacteria that produce toxins and are characterized by affecting the superficial fascia, subcutaneous tissue, subcutaneous fat

with nerves, arteries and veins, and deep fascia. It is accompanied by local pain, fever, and systemic toxicity [1,2]. If acute odontogenic infections become complicated, they can spread to deep spaces and may require aggressive surgical management, which can become complicated and even turn into necrotizing fasciitis [3,4].

Necrotizing fasciitis is a rapidly spreading infection involving fatty tissue and necrotic facial surfaces that include superficial skin [5]. It is a severe and progressive bacterial infection, with extension of necrosis and spread to surrounding tissues, associated with systemic toxicity, this requires early and aggressive multidisciplinary management, since its rapid dissemination and involvement of anatomical structures will determine the prognosis of the patient [6]. Necrotizing fasciitis or also called: streptococcal gangrene, synergistic cellulitis, non-clostridial anaerobic cellulitis, necrotizing cellulitis, fourmier's gangrene, necrotizing erysipelas, among other names, is a bacterial infection, severe, progressive, with rapid necrosis and dissemination through



different tissues; it is related to systemic toxicity and high mortality rate. It is called craniocervical necrotizing fasciitis when it is located in the head and neck and cervicofacial necrotizing fasciitis when it is on the face and neck, it is also important to mention that its location in these regions is extremely rare, being more frequent the location of necrotizing fasciitis in the pelvis and thoracic limbs, abdomen and / or genitals; in these other areas it is called gangrene or Fournier syndrome, melaney's synergistic gangrene, and clostridial myonecrosis [6].

Necrotizing fasciitis is a polymicrobial disease, mentioning in the literature that these bacteria generate gases and endotoxins that participate in the development of the disease. Two main types have been described: type I necrotizing fasciitis is polymicrobial, associated with anaerobes (among these bacteroides, clostridium, peptostreptococci) and some facultative anaerobes (non-A streptococci) and enterobacteria, which act synergistically. Necrotizing fasciitis type II (or also called streptococcal), is a monomicrobial infection, produced by group A beta-hemolytic streptococci (to a lesser extent C and G), and *Staphylococcus aureus* found very rarely. The most affected patients are immunocompromised, with some type of uncontrolled chronic condition, which makes their speedy recovery more difficult and in turn predisposes greater susceptibility to complicate the patient's health status [7].

Cervicofacial necrotizing fasciitis can originate secondary to a dental infectious focus (tooth with cavities) or involvement of a second or third molar that is about to erupt or in poor condition, it is very rare to associate necrotizing fasciitis with some traumatic event, pharyngeal abscess/tonsil, sinusitis, adenitis or infections due to tumors in the cervicofacial region, the clinical characteristics presented by patients with necrotizing cervicofacial fasciitis vary according to the stage and evolution or progression of the disease. Four main clinical signs are mentioned in the literature to suspect necrotizing fasciitis, which are: edema and induration that is found beyond the erythematous area, blisters or violaceous/purple macules, crepitus (due to cutaneous emphysema) and associated adenitis [8,9].

According to the US centers for disease control and prevention, the incidence of necrotizing fasciitis is estimated to be 500-1,000 cases per year in the United States, with an annual incidence rate of 0.4 cases per 100,000 populations [10]. While in Western Europe there is one case per 100,000 inhabitants [11]. On the other hand, the national institute of statistics indicates that since 2009 there have been 54 deaths due to necrotizing fasciitis in Spain; of which 57.4% were men, 64.8% older adults over 70 years [12]. It should be mentioned that *Staphylococcus aureus* is a rare cause of necrotizing fasciitis, appearing only in 0.1/100,000 inhabitants. Necrotizing fasciitis in the United States has an incidence of approximately 1,000 cases per year or 0.04 cases per 1,000/persons/year, this incidence had a noticeable increase between the years 1980 to 2000, although the exact reason is not known, possibly this. The increase is in relation to the increase in virulence and bacterial resistance. In the United Kingdom between 1995 and 2006, 0.24% of admissions to intensive care units were due to necrotizing fasciitis and the hospital stay in intensive care was 21 days with an average of 32 days hospitalized for patients who survived from necrotizing fasciitis and 12 days of hospitalization for those who did not survive [13].

Mortality from necrotizing fasciitis continues to be alarmingly high with reports that vary between 6-76% and the delay in diagnosis and its surgical approach is the main determinant of mortality [14]. This incidence of necrotizing fasciitis has increased significantly in recent years, probably in relation to the aging of the population and the presence of a greater number of immunosuppressed patients [15]. In Mexico, there are no current or prospective studies reporting epidemiological data on necrotizing cervicofacial fasciitis. The study of necrotizing fasciitis as a complication of odontogenic infection is an entity rarely studied in Mexico, high frequencies are deduced, and however there are not the necessary reports to be able to conclude this

situation. The management of necrotizing cervicofacial fasciitis, as in other diseases where there is the presence of necrosis, is as expressed in the literature and in the clinical practice guidelines, local and from different countries, treatment is with broad-spectrum antimicrobials and early and radical surgery, as well as multidisciplinary management due to the involvement of different medical specialties and given that necrotizing fasciitis (in a generalized way) usually occurs in patients with previous conditions (mainly immunocompromise) although there are various etiological factors and their association with different bacteria [16].

In the case of cervicofacial necrotizing fasciitis, it is generally secondary to a dental septic focus. The diagnosis is clinically corroborated by surgical exploration, taking a microbial culture and confirmatory histological study of necrotizing fasciitis, when the clinic grants a large suspicion of necrotizing fasciitis, surgery should not be postponed until the tomographic images are obtained, surgical debridement should be performed immediately, since there is a high incidence of false positives [17,18]. The treatment of necrotizing cervicofacial fasciitis secondary to odontogenic infections involves multidisciplinary management, including hemodynamic and respiratory support (generally in charge of internal medicine or the intensive care unit), early and extensive surgical debridement along with antibiotics.

Some antibiotics for the management of cervicofacial necrotizing fasciitis are: penicillins, generally combined with clindamycin-type lincosamides, carbapenems, some reports mention ampicillin with sulbactam in early stages, another antibiotic scheme is with clindamycin and metronidazole, and in severe cases he has used imipenem, meropenem, vancomycin, among others. The choice of antibiotic should be focused on the result of the bacterial culture resulting from the biopsy of the tissue with necrotizing fasciitis in the initial surgical debridement. Other therapeutic measures include: intravenous immunoglobulins, hyperbaric oxygen, anti-tumor necrosis factor antibodies, post-exposure prophylaxis, and management with negative pressure therapy, among others. Of all the treatments, the gold standard is always antibiotics+surgical debridement (preferably at 24 hours) and supportive therapy that include surgical dressing and scrubbing. Mortality rates have been cited as a range of 50% to 73% [19-25]. For all the above mentioned, this research arises, to determine the frequency of cervicofacial necrotizing fasciitis as a complication of odontogenic abscess in the maxillofacial surgery service of the hospital de especialidades "Dr. Antonio Fraga Mouret", national medical center "La Raza", IMSS; for a year. As well as identify epidemiological and clinical data and comorbidity factors for the development of this disease.

Materials and Method

A descriptive, retrospective, cross-sectional study was carried out for one year (2014). Including all the patients (universe made up of six patients) with a diagnosis of odontogenic abscess who developed as the main complication: cervicofacial necrotizing fasciitis, in turn, all these patients should have been treated in the maxillofacial surgery service of the specialty hospital: "Dr. Antonio Fraga Mouret", of national medical center "La Raza", (IMSS) during 2014, taking into account those patients who, prior to necrosis, had been preceded by an odontogenic abscess and upon arrival at the maxillofacial surgery service presented the presence of necrosis and/or persistence of the abscess (**Figure 1a** and **Figure 1b**). Later the management was antibiotic and immediate radical surgical (**Figure 2**). Also all the patients that made up the sample of this study signed an informed consent to participate in this research, which was followed under the terms and guidelines of the local and ethics committee of the specialty hospital of national medical center "La Raza". In addition, the researchers (authors) guaranteed and took care of the identity of each one of them, maintaining their privacy and anonymity. All patients underwent a computed tomography upon admission, control and post-

surgical, it is worth mentioning that regardless of waiting for the result of the tomography, the first step was debridement of necrotic tissue in the operating room and the tomography served to corroborate the diagnosis clinical.

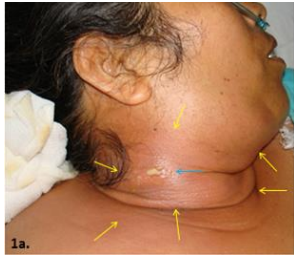


Figure 1a: Female in early stage of cervicofacial necrotizing fasciitis, secondary to an odontogenic abscess involving the right buccal and submandibular spaces, submental and lateral and anterior cervical face (abscess with yellow arrows) and fistula (blue arrow).

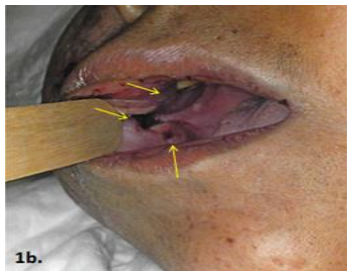

Figure 1b: Presence of necrosis in the mucosa of the right buccal space (yellow arrow).

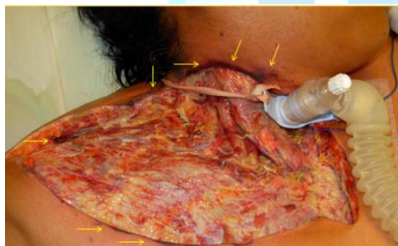

Figure 2: Surgical approach for necrotizing cervicofacial fasciitis, after debridement of necrotic tissue secondary to cannulation and drainage of odontogenic abscess, persistence of necrosis at surgical edges (yellow arrows).

A tissue biopsy was performed and an immediate intervention was carried out, performing surgical debridement under general anesthesia, the tissue sample with fasciitis was taken (in any of the stages, either the initial stage or in the necrotizing phase) before making the first incision and excision of tissue, considering that the microbiota is mostly anaerobic, a portion of the tissue sample is sent to the central laboratory of the specialty hospital to obtain a bacterial culture and antibiogram (the latter in order to indicate the appropriate antibiotic and according to the bacteria found) and the other section to pathology for histological study; In the same surgical time, the intraoral septic focus is eliminated, by performing the dental extraction of the tooth that caused the abscess and subsequent cervicofacial necrotizing fasciitis secondary to odontogenic abscess (**Figure 3a** and **Figure 3b**).

The patient was hospitalized in the maintenance phase (performing cures by the maxillofacial surgery service, with schedule, with approximately each cure being performed every 8 hours) likewise the patient was monitored in a multidisciplinary manner, waiting around 3-5 days in what perform the cultivation and throw the result. Surgical intervention was performed as many times as necessary, in order to

eradicate necrotizing fasciitis. During the study the report was made, later data were collected and all the data in relation to the factors, characteristics, occupied spaces in the abscess that conditioned the cervicofacial necrotizing fasciitis, etc. were reported in a file and they were analyzed in a statistical program, to subsequently report the results.

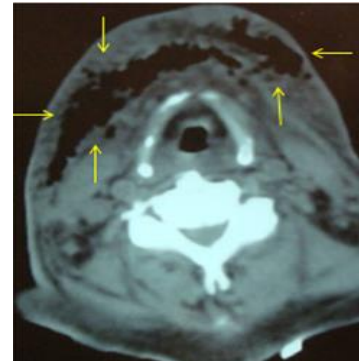


Figure 3a: Computed tomography, axial sections, with the presence of emphysema and images of necrotizing cervicofacial fasciitis with involvement of the right submandibular space, submental (yellow arrows).

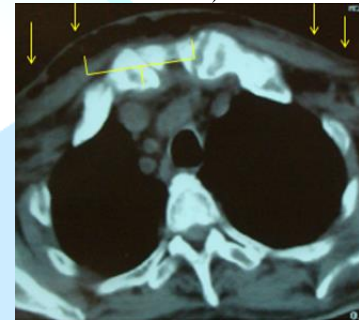


Figure 3b: Extension of necrotizing fasciitis to anterior and superior mediastinum (yellow arrows).

The inclusion criteria for this study were: patients of any gender, of legal age, who had been treated in the maxillofacial surgery service of the specialty hospital of the national medical center “La Raza” during 2014 (from January to December), patients diagnosed with necrotizing fasciitis secondary to odontogenic abscess. The exclusion criteria were: patients with a diagnosis of necrotizing fasciitis without a history of cervicofacial abscess or dental septic focus, those patients who are minors and/or 17 years of age (since for the Mexican Institute of Social Security in Mexico, they are considered child patients, all those under 17 years of age, subsequently patients aged 17 or over should be treated in the adult service), patients with a diagnosis of necrotizing cervicofacial fasciitis with another origin (tonsillar, non-odontogenic cervical abscess, dissemination by contiguity or other of some infection of non-dental origin necrotizing cervicofacial fasciitis secondary to trauma to chemotherapy or radiotherapy, among others). In this study, the indications of the local ethics committee of the specialty hospital of the national medical center “La Raza” were followed, safeguarding the integrity and anonymity of all participating patients, as well as signed informed consent from each of the patients included in the study, always keeping your data confidential.

Analysis of Data

The data were collected in a file, age, intraoral septic focus (teeth) that caused odontogenic abscess and subsequently developed necrotizing fasciitis as a complication were considered as variables, likewise the aponeurotic spaces involved in necrotizing fasciitis were counted and mentioned cervicofacial secondary to odontogenic abscess (they were



divided into facial and cervical aponeurotic spaces), finally the treatment provided to the patients was reported, the data were analyzed and the results were reported in means and percentages in relation to the different variables.

Results

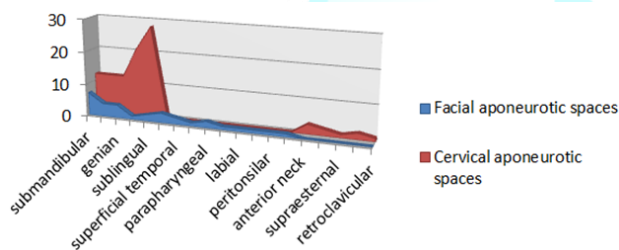
Over the course of one year (2014), a sample of 6 patients with a diagnosis of necrotizing cervicofacial fasciitis secondary to odontogenic abscess was obtained (Table 1). No significant difference

was found with respect to gender since 3 patients were women and 3 men, so the sample was equitable 50% each of the genders, the mean age was 69.16 years, with a maximum range of 86 years and the minimum 40 years. Regarding the aponeurotic spaces involved (Graph 1) the average number of aponeurotic spaces involved by necrotizing fasciitis secondary to odontogenic abscess was 6.5, the patient who had more spaces affected by necrotizing cervicofacial fasciitis reported 14 affected aponeurotic spaces, the one with the least affected aponeurotic spaces was a patient with only two affected spaces (left submandibular and genian); the most affected side was the right (Graph 2).

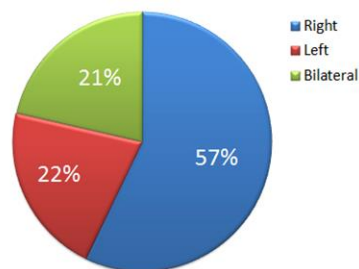
Sheet number	Gender	Age	Intraoral septic focus causing tooth abscess	Number of aponeurotic spaces affected	Facial aponeurotic spaces	Cervical aponeurotic spaces	Treatment
1	Male	66	Second molar extracted	Five	Right submandibular, genian and parotid; submental	Anterior neck	DsQx, L
2	Male	70	Lower right third molar	Fourteen	Submental, bilateral submandibular and sublingual, infratemporal, superficial and deep temporal and left parapharyngeal	Left anterior and lateral neck, suprasternal, supraclavicular and retroclavicular	C, D, E, DsQx, L
3	Male	86	1 st , 2 nd , 3 rd upper and lower right molars	Seven	Submandibular, vestibular, genian, labial, periorbital, superficial and deep temporal right	-	C, D, E, DsQx, L
4	Female	83	Central incisors, lateral incisors and bilateral upper canines, 1 st and 2 nd right lower premolars	Six	Submental, right submandibular and peritonsillar	Supraclavicular, anterior and lateral neck	C, D, E, DsQx, L
5	Female	70	Central and lateral incisors, canines and lower right 1st premolars	Five	Right submental, submandibular, genian, infratemporal and canine	-	C, D, E, DsQx, L
6	Female	40	1 st , 2 nd , 3 rd left molars and 1 st lower right molar	Two	Left submandibular and genian	-	E, DsQx, L

Abbreviations: C-Canalization, D-Drainage, E-Tooth Extraction, DsQx-Debridement of Necrotic Tissue, L-Surgical Scrub.

Table 1: Frequency of necrotizing cervicofacial fasciitis as a complication of odontogenic abscesses.



Graph 1: Aponeurotic spaces involved by necrotizing fasciitis secondary to odontogenic abscess.



Graph 2: Side most affected by necrotizing fasciitis secondary to odontogenic abscess.

The most affected aponeurotic spaces were the facial ones (27 in total), only 9 cervical aponeurotic spaces were reported in total of all patients; the anterior face of the neck being more affected. The aponeurotic space most affected by cervicofacial necrotizing fasciitis secondary to odontogenic abscess was the submandibular, followed by the submental and genian. The maxillofacial surgery service of the specialty hospital of the national medical center "La Raza" performed the empirical primary antibiotic management, based on the clinical practice guidelines and what was reported in the literature, prescribing clindamycin and some cephalosporin (it should be mentioned that none of the patients of the study sample, I mention an allergy to penicillin, which is why the antibiotic scheme was thus decided). Surgical

management was: in four patients cannulation and drainage of persistent abscess or drainage of purulent collection, in all (6 patients) surgical lavage was performed, 3 patients required more than 4 surgical washes, the other half of patients between 2 and 3 surgical washes. All patients (six) underwent debridement of necrotic tissue (the same three that required more than 4 surgical washes, were the same that underwent surgery in multiple debridement due to extension of necrotizing fasciitis, complications such as mediastinitis or dissemination to the thorax or cranial region and/or persistence of necrosis in the center or edges of the surgical wound). 5 patients underwent intraoral septic foci extraction and only one patient developed odontogenic cervicofacial necrotizing fasciitis after an odontogenic abscess by extraction of a second molar.

Discussion

There are reports in the literature on necrotizing fasciitis where they mention different etiologies related to this disease, in all of them they agree that it is a rare entity rarely associated with the facial region, it is generally found in other areas of the body (pelvis and thoracic limbs) such and as it was initially described and mentioned by several authors, for example farrier, sepúlveda, engel and collaborators among others [6,8,9]. Like these authors, in this study few cases of necrotizing fasciitis in the cervicofacial region are reported. On the other hand, this article presents the cases of necrotizing cervicofacial fasciitis secondary to odontogenic abscess whose septic focus was one or several teeth (without having a predilection for any specific one), which is different from other studies such as those of the authors: Subhashraj [26] and Sepúlveda [8] who mention that the septic foci frequently related to necrotizing cervicofacial fasciitis are the second and third molars. In the maxillofacial surgery service, of the specialty hospital, of national medical center "La Raza", the initial diagnostic management is agreed and followed as mentioned by the authors Stamenkovic, Lew [27] and Hohenboken et al., [28] who mention that a tissue biopsy should be performed for diagnosis and sent to pathology for confirmation, however, in cases where there is clinical evidence, surgical management should be carried out immediately.

In this work, the intraoperative biopsy was performed and sent a pathology having a preliminary while the surgical resection and



surgical lavage were being performed, most of the patients presented had evident data of necrosis, such as change in color and texture of the skin and / or mucosa, one patient reported paresthesia and palpation. When the affected region was indurated, which was associated with the facial nerve, the rest of the patients showed necrotic fascia when the incision was made, and even in two of the cases with cervical extension to deep spaces of the neck, involvement of the muscular plane was observed, in the same way in one of the patients (who was obese) he presented lysis of adipose tissue.

There are very few studies in Latin America, but especially in Mexico, that show updates on the frequency of odontogenic cervicofacial necrotizing fasciitis, and locally in medical centers of tertiary hospital care, which are those hospitals with the highest concentration and referral of patients from different hospitals, clinics and health centers, such as the national medical center "La Raza" (where this study was carried out), and even more specific in the maxillofacial surgery service of the same hospital; there has not been a continuous and updated report of the cases that present necrotizing cervicofacial fasciitis. Which influences the importance of conducting this study and providing long-term follow-up of the cases reported and diagnosed as necrotizing cervicofacial fasciitis.

A retrospective study, published by Sosa Milke et al., [5] who makes mention of cases treated in one of the hospitals of the national medical center "La Raza" (in the infectology Hospital), the difference with this study lies in the number of patients sampled, the type of research carried out, which in this study The authors themselves are the ones who carried out the data collection, patient management and control thereof, while in Dr. Sosa's, a review of clinical records was carried out, the analysis of the aponeuritic spaces involved coincided, as which is of great importance to estimate the prognosis of the patient and for the prediction of surgical approaches and/or the possible spread of infection.

However, it is important to emphasize that continuing to make it possible in the future to estimate the epidemiology of odontogenic cervicofacial necrotizing fasciitis. According to the reports and studies carried out by various authors, on epidemiological data regarding the low incidence of cervicofacial necrotizing fasciitis in various countries, mentioning that there is less than or equal to one patient in each Mexico, these data are not updated, the studies reported by Sosa Milke et al., [5] dates from 2010 and is one of the most up-to-date reports, which has a lag of approximately 10 years taking into account infections of any origin located on the face and neck, compared to the study that is presented only It is specified in the maxillofacial surgery service and that they are of odontogenic origin, which makes it more selective and specific, despite the fact that it is a retrospective study from 2014, a control of all patients who survived the pathological entity was maintained [10-15].

What is proposed with this study, based on and antecedents in what is mentioned in the literature on surgical and pharmacological management, is to prioritize immediate surgical management coupled with empirical antibiotic in a double scheme, in the maxillofacial surgery service a beta lactam is used (penicillin or cephalosporin) and lincosamide (clindamycin). The sample presented was obtained in one year (2014) with which in consecutive years the annotation of a list of new cases was implemented, in order to accumulate data and possibly carry out at the end of this year (2020) a collection of five years of the cases that have had this diagnosis. One of the things that were implemented is the taking of at least two cultures (one on admission before making the first incision and in case the patient has already been treated with canalization and drainage; it was taken from the area with necrotizing fasciitis). It should be noted that the cultures that were carried out were sent a sample to pathology and another to microbiology in order to reinforce the confirmatory diagnosis and, in addition, the intentional search for specific bacteria is being implemented when performing the antibiogram to indicate the

antibiotic management individually. which will be of help for the following new cases, since by relating the behavior of necrotizing fasciitis in the patients that made up the population treated in the maxillofacial surgery service of the specialty hospital "La Raza", national medical center (IMSS), a protocol can be established specific and useful in order to improve management and later teach it in other units medical ades.

Conclusions

The aim of this research is to find the relationship between infectious processes of odontogenic origin and one of the most serious complications such as necrotizing fasciitis. The cause of death in patients with necrotizing fasciitis is usually sepsis in an early stage, and in late stage respiratory failure and multiple organ failure. Early surgical intervention continues to be crucial for the patient's prognosis, in most cases the wound is left open until it is healed by second intention. It is important that treatment is based on early diagnosis, aggressive surgical attitude, and intensive antibiotic therapy. A high diagnostic suspicion is required for early recognition and that patients are treated with aggressive and early surgical debridement. This is the key to therapeutic success, and the reduction in mortality as well as the reduction of the sequelae of this process.

Joint management with intravenous antibiotic therapy with the appropriate spectrum is the second pillar of treatment, as is multisystem support in the ICU. To date, no laboratory or imaging diagnostic method exceeds clinical suspicion in the diagnosis and definition of the moment of initiation of necrotizing fasciitis management. At the specialty hospital: "Dr. Antonio Fraga Mouret", national medical center "La Raza", Mexico city; There are no prospective studies that show clear evidence on the frequency of necrotizing cervicofacial fasciitis as a complication of odontogenic abscess and there are no objective results on the protocol for its management, that is why this research arises to carry out further studies and continue a long-term line of research locally and later with extension to other hospital units.

Acknowledgment

The rest of the maxillofacial surgery, general surgery, intensive care unit, internal medicine, neurosurgery, head and neck surgery, laboratory staff, infectology, operating room and x-rays, who directly or indirectly helped patient care.

References

1. Wang K and Shih C. Necrotizing fasciitis of the extremities (1999) *J Trauma* 32: 179-182. <https://doi.org/10.1097/00005373-199202000-00011>
2. Loudon I. Necrotizing fasciitis, hospital gangrene and phagedena (2000) *Lancet* 334: 1416-1419. [https://doi.org/10.1016/s0140-6736\(94\)90574-6](https://doi.org/10.1016/s0140-6736(94)90574-6)
3. Chattar D, Tulsyan N, Cudjoe E, Onime G and Weinstein L. Necrotizing fasciitis of the head and neck: a report of two patients and review (2002) *Head Neck* 24: 497-501. <https://doi.org/10.1002/hed.10060>
4. Morantes M, Yepes JF and Pinto A. Consideraciones del uso de antibióticos en infecciones odontogénicas *Revista* (2003) *ADM* 60: 185-192.
5. Sosa Milke RJ, Pena Torres LM and Flores VG. prevalencia de fascitis necrotizante odontogénica en el hospital de infectología del centro médico nacional la raza del instituto mexicano del seguro social (2010) *Revista Odontológica Mexicana* 14: 213-217.



6. Farrier JN, Kittur MA and Sugar AW. Necrotizing fasciitis of the submandibular region; a complication of odontogenic origin (2007) *BDJ* 202: 607-609.
7. Parra P, Pérez S, Patino M, Castañeda S and García A. Actualización en fascitis necrotizante (2012) *Semin Fund Esp Reumatol* 13: 41-48. <https://doi.org/10.1016/j.semreu.2011.12.005>
8. Sepúlveda A and Sastre N. Necrotizing fasciitis of the face and neck (1998) *Plast Reconstr Surg* 102: 814-817.
9. Engel J. Calming fears of necrotizing fasciitis, the killer bacteria (1994) *Health News*, University of Toronto, United States.
10. [The Centers for Disease Control and Prevention \(2009\) Group A Streptococcal \(GAS\) disease.](#)
11. Nowak R. Flesh-eating bacteria: Not new, but still worrisome (1994) *Science* 264: 1665. <https://doi.org/10.1126/science.8209244>
12. Davis S, Perri M, Donabedian S, Manierski C, Singh A, et al. Epidemiology and outcomes of community associated methicillin-resistant *Staphylococcus aureus* infection (2007) *J Clin Microbiol* 45: 1705-1711. <https://doi.org/10.1128/JCM.02311-06>
13. George S, Harrison D, Welch C, Nolan K and Friedmann P. Dermatological conditions in intensive care: A secondary analysis of the Intensive Care National Audit and Research Centre (ICNArc) Case Mix Programme Database (2008) *Crit Care* 12: S1 <https://doi.org/10.1186/cc6141>
14. McHenry C, Piotrowski J, Petrinic D and Malangoni M. Determinants of mortality in necrotizing soft tissue infections (1995) *Ann Surg* 221: 558-563. <https://doi.org/10.1097/0000658-199505000-00013>
15. Kaul R, McGeer A, Low DE, Green K and Schwartz B. Population based surveillance for Group A Streptococcal (GAS) necrotizing fasciitis: Clinical features, prognostic indicators, and microbiologic analysis of seventy-seven cases. Ontario Group A Streptococcal Study (1997) *Am J Med* 103:18-24. [https://doi.org/10.1016/S0002-9343\(97\)00160-5](https://doi.org/10.1016/S0002-9343(97)00160-5)
16. [Diagnóstico y Tratamiento de Fascitis Necrosante \(2009\) Secretaría de Salud, United States.](#)
17. Defining the Group A Streptococcal (GAS) toxic shock syndrome. Rationale and consensus definition. The Working Group on Severe Streptococcal Infections (1993) *JAMA* 269: 390-391. <https://doi.org/10.1001/jama.1993.03500030088038>
18. Wong C and Wang Y. The diagnosis of necrotizing fasciitis (2005) *Curr Opin Infect Dis* 18: 101-106. <https://doi.org/10.1097/01.qco.0000160896.74492.ea>
19. Stevens D. Streptococcal toxic shock syndrome associated with necrotizing fasciitis (2000) *Annu Rev Med* 52: 271-288. <http://dx.doi.org/10.1146/annurev.med.51.1.271>
20. Sudarsky L, Laschinger J, Coppa G and Spencer F. Improved results from a standardized approach in treating patients with necrotizing fasciitis (1987) *Ann Surg* 206: 661-665. <https://doi.org/10.1097/0000658-198711000-00018>
21. Wang T and Hung C. Role of tissue oxygen saturation monitoring in diagnosing necrotizing fasciitis of the lower limbs (2004) *Ann Emerg Med* 44: 222-228. <http://dx.doi.org/10.1016/S0196064404003038>
22. Sarani B, Strong M, Pascual J and Schwab C. Necrotizing fasciitis: Current concepts and review of the literature (2009) *J Am Coll Surg* 208: 279-288. <http://dx.doi.org/10.1016/j.jamcollsurg.2008.10.032>
23. Stevens D. Streptococcal toxic-shock syndrome: Spectrum of disease, pathogenesis, and new concepts in treatment (1995) *Emerg Infect Dis* 1: 69-78. <http://dx.doi.org/10.3201/eid0103.950301>
24. Shimizu T and Tokuda Y. Necrotizing fasciitis (2010) *Inter Med* 49: 1051-1057. <https://doi.org/10.2169/internalmedicine.49.2964>
25. Elliott D, Kufera J and Myers R. Necrotizing soft tissue infections. Risk factors for mortality and strategies for management (1996) *Ann Surg* 224: 672-683. <https://doi.org/10.7860/JCDR/2013/5535.3240>
26. Subhashraj K, Jayakumar N and Ravindran C. Cervical necrotizing fasciitis: An unusual sequel of odontogenic infection (2008) *Med Oral Patol Oral Cir Bucal* 13: E788-E791. http://www.medicinaoral.com/pubmed/medoralv13_i12_pE788.pdf
27. Stamenkovic I and Lew P. Early recognition of potentially fatal necrotizing fasciitis: The use of frozen section biopsy (1984) *N Engl J Med* 310: 1689-1693. <https://doi.org/10.1056/NEJM198406283102601>
28. Hohenboken J, Anderson F and Kaplan E. Invasive Group A Streptococcal (GAS) serotype M-1 outbreak in a Long-Term Care Facility (LTCF) with mortality (1994) En: presented at the 34th interscience conference on antimicrobial agents and chemotherapy, United State 189.