



Management of Type I Placement in the Esthetic Zone in a Partially Edentulous Patient: Case Report

Gracia Alvarenga^{1*}, Vilma Umazor², Sarahí Avila³, Hugo Romero⁴ and Juan Guifarro⁵

Affiliation

¹Periodontics and Implant Dentistry, School of Periodontics, Universidad Católica de Honduras (UNICAH) Tegucigalpa, Honduras

²Department of Periodontics, Universidad Nacional Autónoma de Honduras, Honduras

³Department of Periodontics, Universidad Católica de Honduras, Honduras

⁴Department of Stomatology, Universidad Nacional Autónoma de Honduras, Honduras

⁵Department of maxillofacial surgery, Hospital Escuela, Tegucigalpa, Honduras

***Corresponding author:** Gracia Alvarenga, Private Practice, Periodontics and Implant Dentistry, School of Periodontics, Universidad Católica de Honduras (UNICAH) Tegucigalpa, Honduras, E-mail: gfortin@unicah.edu

Citation: Alvarenga G, Umazor V, Avila S, Romero H and Guifarro J. Management of type I placement in the esthetic zone in a partially edentulous patient: Case report (2020) *Dental Res Manag* 4: 23-26.

Received: Mar 04, 2020

Accepted: Mar 20, 2020

Published: Mar 25, 2020

Copyright: © 2020 Alvarenga G, et al., This is an open-access article distributed under the terms of the Creative Commons Attribution License, which permits unrestricted use, distribution, and reproduction in any medium, provided the original author and source are credited.

Abstract

Objective: There are several developed protocols for implant placement. When treating the esthetic zone different alternatives can be presented according to case variations and implications of the treatment planning and clinical challenges. Immediate implant placement protocols, favor both the patient and the clinician. This particular technique reduces time needed throughout the planning and performing. This document presents the clinical outcome of immediate implant placement in esthetic zone.

Clinical Considerations: This case report describes the treatment of a 33 years old patient that requested the rehabilitation of missing teeth in the esthetic zone, previously lost due to facial trauma. All medical and clinical implications were taken into consideration to establish the treatment plan. Radiographic analysis and digital planning were carried through, accordingly. In the second surgical phase of implant treatment, the augmentation of keratinized tissue, in the treated area had no significant results, therefore a third surgery was performed “vestibuloplasty”.

Conclusions: The proper planification of immediate implant placement should be ideally included, all the diagnostic tools available, granting the complete visualization of the patient’s conditions, permitting the development of the ideal treatment plan. The treatment with osseointegrated implants inserted immediately after the tooth extraction could be an implantological secure alternative, achieving a successful treatment. However, there’re still several issues that should be addressed. Further investigation is needed.

Keywords: Implant therapy, Bone implant contact, Vestibuloplasty, Osteotomy, Periodontal ligament.

Abbreviations: BIC-Bone-Implant Contact, PDL-Periodontal Ligament, CAIS-Computer-Assisted Implant Surgery, CBCT-Cone Beam Computed Tomography, DBBM-Deproteinized Bovine Bone Mineral.

Introduction

Implant therapy is today widely regarded as a reliable treatment option to replace the missing teeth, both for functions and esthetics. This technic has revolutionized dental practice when incorporating oral rehabilitation therapy in patients that for one reason have lost their natural teeth [1]. The original treatment protocols of the 1970s and 1980s required fully healed alveolar ridges before implants were placed [2]. This strategy was thought to ensure maximum Bone-Implant Contact (BIC) because the dimensions of the osteotomy could be tailor-fit to the implant [3].

Patients demand for shorter treatment duration, which generates the need of modifying implant placement protocols, stating early or immediately placement after tooth extraction, which cuts off the period of socket healing. The obvious difference between an osteotomy and an extraction socket is that the ridge results in irregular geometry. Upon implant placement, this irregular geometry creates some regions of BIC

but also some regions with gaps between the bone and implant. Clinical data demonstrates that immediate post extraction implants can undergo osseointegration, but the biomechanical mechanisms responsible for this success are not entirely clear. Previous study had demonstrated that extraction sockets heal significantly faster than osteotomies, and the underlying reason for this faster repair was due to Wnt-responsive osteoprogenitor cells residing in the Periodontal Ligament (PDL) that remained attached to the socket wall after tooth extraction.

In implant surgery its critical to achieve the optimal implant position because, it compromises the prosthetic design. The correct position in restorative driven implant placement can offer a long-term stability, allowing for successful esthetic and function, as well as optimal occlusion and implant loading. Static CAIS Surgery involves virtual planning of the implant placement in the optimal restorative position and utilizes surgical guides to help the surgeon to perform the

Citation: Alvarenga G, Umazor V, Avila S, Romero H and Guifarro J. Management of type I placement in the esthetic zone in a partially edentulous patient: Case report (2020) *Dental Res Manag* 4: 23-26.

osteotomy and site preparation in an accurate and efficient manner. Several recent clinical studies have compared the pre-surgical planned implant position to the final post-surgical placement to determine the accuracy and predictability of the static CAIS technique. In this technique, an initial CBCT examination is conducted, and that offers detailed 3D representation of the alveolar bone and teeth [4].

The common goal of these systems is the achievement of maximal surgical safety on the basis of an exact diagnosis, virtual planning and high accuracy for the surgical transfer. The dynamic or active systems match the 3D visualization, in addition to the virtual planning data of a patient, to its actual real position during the surgical procedure. Surgical tools are likewise real time visualize as virtually corresponding within the patient's 3D data set so that a comparison between simulation and its actual implementation is possible at any time during the surgical procedure [5]. Block and Kent presented a study with 96.8% of success in a 2 year follow up of 62 implants that were placed post extraction with hydroxyapatite that was used as filling material in peri-implant defects.

The objective of this article is to present a clinical evaluation and the follow-up of the treatment with osseointegrated implants through the technique of immediate insertion after the tooth extraction.

Case Report

A 33-year-old male with a history of having an accident with a saw, introduces himself to the "Monseñor Agustín Hombach Hospital". The patient refers to have the fracture of the crowns of his anterior teeth due to trauma. He assumed to have back of his teeth. Clinical examination showed that the patient presents the use of a provisional removable in the upper anterior sector. The root of the teeth 1.2, 1.1 and 2.1 is observed in the tomographic examination. Patient doesn't have any relevant medical history. During the first visit alginate impressions, periodontal charting, clinical photographs, and comprehensive oral examination were completed. A periapical radiograph was taken in the anterior teeth. You can observe in the radiography that the roots were not long enough to be fixed prosthetically. The immediate placement implants were proposed to the patient (Figure 1).

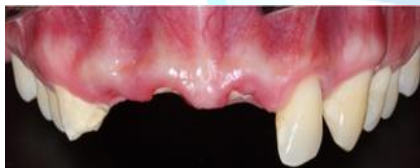

Figure 1: Absence of dental crowns of the teeth 1.2, 1.1 and 2.1.

Surgical Planning

The CBCT and scanning the print models were used to know where the correct implant placement should be, considering the optimal restorative position with the help of the surgical guides. As shown in Figure 2.

Surgical Procedure

After the placement of the local infraorbital anesthesia and infiltrative technique (with lidocaine 2%) atraumatic extraction was performed with the use of periostomes to avoid damage to the cortical plates and allow an immediate implant placement. An incision was made on crestal canine to canine, they were vertical buccal incisions a distally oriented for the purpose of flap relief. Using a periosteal elevator, mucoperiosteal flaps were elevated sufficiently to visualize the alveolar ridge anatomy. The diameter of the socket was approximately 7 mm with a dehiscence and fenestration. The initial bur was used to mark the initial drilling depth, followed by the drilling protocol, periapical radiographs were taken to analyze implant 3D positioning and their relation to adjacent and opposing teeth. The drilling in the right

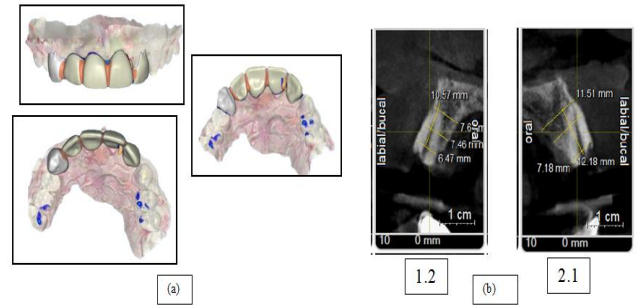


Figure 2: a) The scan and digital design, b) Tomographic cuts.

Position implants were placed manually. Because of the socket defect xenograft was placed in the gap left after placing the implants and outside the vestibular wall, the collagen membrane was placed on the bone graft and settled with sutures below the palatine flap. Once the guided bone regeneration was completed the flap was repositioned and sutured (Figure 3). A month postoperative, provisionalization removal prosthesis was left.

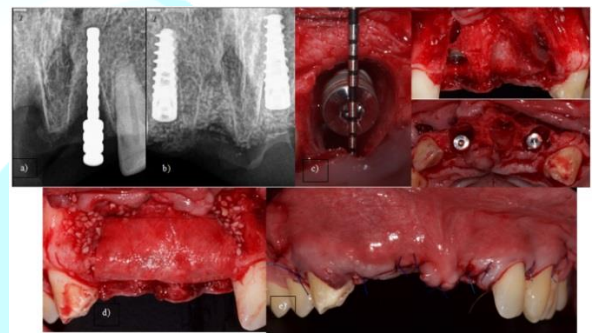


Figure 3: a) Periapical control radiography, b) Periapical implant radiography, c) Implant placed in the alveolar, d) Xenograft and collagen membrane placed, and e) Flap repositioning.

Second Stage Surgery

At 6 months, a soft tissue augmentation procedure at the second stage surgery was performed. The flap was relief in the same incisions that were performed in the first surgery. The connective tissue graft was taken from the palate in the area of the premolars and the placement of the healing abutment with flap repositioning (Figure 4).

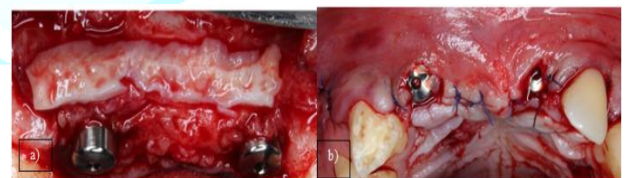


Figure 4: a) The placement of the soft tissue graft and the screwing of the healing abutment, b) Repositioning of flap with simple sutures.

Prosthetic Phase

A month later the healing screws were change for a higher length. At clinical evaluation it was observed that apparently there was no formation of keratinized tissue (Figure 5).

For a better control a CBCT was indicated (Figure 6). The impression was taken with lightweight silicone for the manufacture of the provisional after a month of surgery, using an open tray impression post; they were splinted with inlay pattern resin. The impression of the antagonist was taken with alginate and bite registration with occlusal (Figure 7).

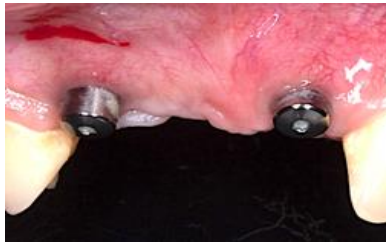


Figure 5: Healing abutment change for a higher length.

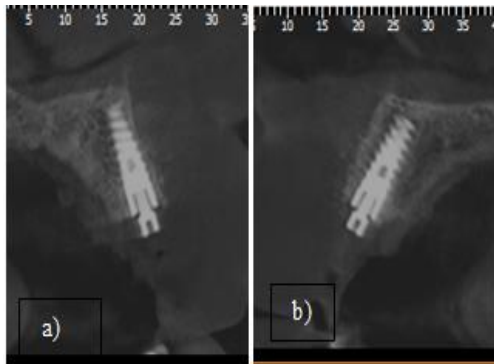


Figure 6: Sagittal Cut of the CBCT a) 1.2, b) 2.1.

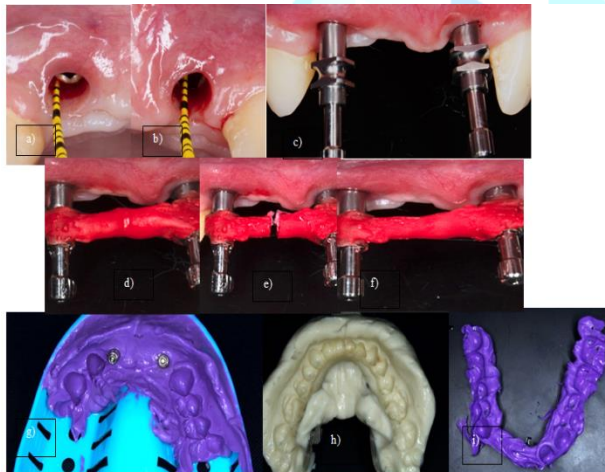


Figure 7: a) Soft tissue Deeping of the 1.2 (3 mm) b) 2.1 (5 mm) c) Placement of the open tray abutment d) First layer of inlay pattern resin, e) Cut of the first layer of inlay pattern resin for better stability f) Second layer of inlay pattern resin, g) Silicone impression with the open tray abutment, h) Alginate antagonist impression i) Bite registration with occlusal.

After 3 weeks, the screw retained provisional was placed with a torque of 30N, made of acrylic resin, the chimney was covered with acrylic resin and polished with pome stone. 2 months later the patient came back with discomfort in the zone 1.2. A second surgical intervention was performed in order to augment the amount of keratinized tissue and remove the frenulum. The technic that was used to gain more keratinized tissue was the vestibuloplasty, raising a flap with a horizontal incision 2 mm above the keratinized tissue around the implants, the flap was repositioned apically, and the frenulum was removed to release the tension. 4 weeks after the surgery it can be seen greater depth of the vestibular and keratinized tissue. It was decided to wait longer for better healing and then be able to make the final impression for the final crowns (**Figure 8**).

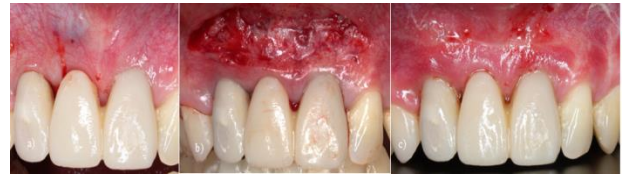

Figure 8: a) The provisional screwed, the chimney covered with resin acrylic and polish b) Vestriculoplasty was performed and the frenulum removes to gain more keratinized tissue. c) 4 weeks after the second surgery performed to gain keratinized tissue.

Discussion

The predictability of dental implants has allowed a close interrelationship between implantology and rehabilitation. This study assesses the clinical results of the treatment with immediate implant placement, a technique that was introduced by Schulte in 1978, which has been progressively incorporated into general implantology practice with positive results [6].

The integrity and stability of the facial bone wall is a critical determinant for stable esthetic outcomes long-term. Recently 3D radiology predominantly using CBCT has provided a noninvasive method to assess the status of the facial bone. This technology does have limitations, as intact but thin facial bone may not always be detectable on the reformatted images [7]. In this case even though the surgery was planned as a guided implant placement intervention the CBCT's inaccuracy causes the disposal of the surgical guide and led to the application of the conventional free-hand method. Given appropriate pre-surgical planning, including 3-dimensional radiographic imaging and proper case selection, freehand surgery may be an acceptable alternative. Therefore, it is critical to identify the factors that affect the accurate positioning of the implant fixture [8].

The facial bone walls that were reconstructed with a combination of autogenous bone chips and DBBM particles were largely intact at an average of 7 years following implant placement. Of clinical significance was the stability of the position of the peri-implant mucosa throughout the observation period, which, it may be speculated, could be due to the underlying thick facial bone [9].

The biological phenomena that occur after tooth extraction have been studied in studies with experimental animals and in biopsies with patients [10]. It has been shown in different studies that the healing of the socket and the progressive replacement of bone tissue last between 4-6 weeks, although the final remodeling can last up to 4 months [11].

After the extraction, important morphological changes occur. Approximately between 5-7 mm the horizontal distance or lingual vestibule width is reduced after a period of 6-12 months after the extraction, which represents almost 50% of the initial alveolar width. These horizontal changes are accompanied by changes in height or apicoronal with a reduction of 2 to 4.5 mm, especially if there are several extractions performed [12].

Immediate implant placement can be used in ideal clinical conditions. The most important requirements are a fully intact facial bone wall with a thick wall phenotype (>1 mm) and a thick gingival phenotype. When both conditions are present, there is a low risk for recession of the facial mucosa and orofacial flattening of the soft tissue profile at the neck of the implant prosthesis. In addition, there should be an absence of acute purulent infection in the extraction site and a sufficient bone volume apically and palatally of the extracted root to allow a correct 3D implant positioning with good primary stability. It should be noted that these conditions are seldom encountered in the



anterior maxilla. According to various CBCT studies, a thick wall phenotype is rarely present in the anterior maxilla [13-15].

The advantages of this technique include a significant reduction in the number of surgical interventions and over time. The socket can also be used as a guide for the orientation of the implant. Other advantages are the preservation of the bone around the extraction and the good response of the soft tissue that improve the final aesthetic [16].

In this study it was observed that after a period of 6 months, a statistically significant increase of soft tissue volume was achieved applying the roll enveloping flap. In another comparative study in the maxilla, three different soft tissue augmentation techniques were compared regarding the gain in peri-implant soft tissue volume [17].

Conclusions

The treatment with osseointegrated implants inserted immediately after the extraction, which can be an implantological alternative that can achieve success in the treatment. Performing careful surgical technique that would include the least traumatic exodontics possible can help soft tissue to maintain its anatomy. This technic proves a good primary stability, sometimes it is used as a guided to regenerate hard and soft tissue, using biomaterials. It also can allow and immediate loading and improving the quality of the treatment form the patient's point of view and preventing morphological reductions of the alveolar bridge edentulous.

References

1. Misch CE. Contemporary implant dentistry (1999) Mosby, United States.
2. Brånemark PI, Hansson BO, Adell R, Breine U, Lindström J, et al. Osseointegrated implants in the treatment of the edentulous jaw. Experience from a 10-year period (1977) *Scand J Plast Reconstr Surg Suppl* 16: 1-13.
3. Heimke G. Osseo-integrated implants (1990) CRC Press, United States.
4. Kiatkroekkrai P, Takolpuckdee C, Subbalekha K, Mattheos N and Pimkhaokham A. Accuracy of implant position when placed using static computer-assisted implant surgical guides manufactured with two different optical scanning techniques: A randomized clinical trial (2019) *Int J Oral Maxillofac Surg* 49: 7-14. <https://doi.org/10.1016/j.ijom.2019.08.019>
5. Dreiseidler T, Neugebauer J, Ritter L and Lingohr T. Accuracy of a newly developed integrated system for dental implant planning (2009) *Clini Oral Implants* 20: 1191-1199. <https://doi.org/10.1111/j.1600-0501.2009.01764.x>
6. Chen ST, Wilson TG and Hammerle C. Immediate or early placement of implants following tooth extraction: Review of biologic basis, clinical procedures and outcomes (2004) *Int J Oral Maxillofac Implants* 19: 12-25.
7. Razavi T, Palmer RM, Davies J, Wilson R and Palmer PJ. Accuracy of measuring the cortical bone thickness adjacent to dental implants using cone beam computed tomography (2010) *Clin Oral Implants Res* 21: 718-725. <https://doi.org/10.1111/j.1600-0501.2009.01905.x>
8. Choi W, Nguyen BC, Doan A, Girod S, Gaudilliere B, et al. Freehand versus guided surgery factors influencing accuracy of dental implant placement (2017) *Implant Dent* 26: 500-509. <https://doi.org/10.1097/ID.0000000000000620>
9. Chen ST and Buser D. Esthetic outcomes following immediate and early implant placement in the anterior maxilla-A systematic review (2014) *Int J Oral Maxillofac Implants* 29: 186-215. <https://doi.org/10.11607/jomi.2014suppl.g3.3>
10. Boyne PJ. Ossues repair of the post extraction alveolus in man (1966) *Oral Surg Oral Med Oral Pathol* 21: 805-813. [https://doi.org/10.1016/0030-4220\(66\)90104-6](https://doi.org/10.1016/0030-4220(66)90104-6)
11. Evian CI, Rosenberg ES, Coslet JG and Corn H. The osteogenic activity of bone removed from healing extraction sockets in human (1982) *J Periodontol* 1-5. <https://doi.org/10.1902/jop.1982.53.2.81>
12. Johnson K. A study of the dimensional changes occurring in the maxilla following tooth extraction (1969) *Aust Dent J* 14: 241-244. <https://doi.org/10.1111/j.1834-7819.1969.tb06001.x>
13. Buser D, Weber HP and Brägger U. The treatment of partially edentulous patients with ITI hollow-screw implants: Surgical evaluation and surgical procedures (1990) *Int J Oral Maxillofac Implants* 5: 165-175.
14. Januário AL, Duarte WR, Barriviera M, Mesti JC, Araújo MG, et al. Dimension of the facial bone wall in the anterior maxilla: A cone-beam computed tomography study (2011) *Clin Oral Implants Res* 22: 1168-1171. <https://doi.org/10.1111/j.1600-0501.2010.02086.x>
15. Vera C, De Kok IJ, Chen W, Reside G, Tyndall D, et al. Evaluation of post-implant buccal bone resorption using cone beam computed tomography: A clinical pilot study (2012) *Int J Oral Maxillofac Implants* 27: 1249-1257.
16. Lazzara RJ. Immediate implant placement into extraction site: Surgical and restorative advantages (1989) *Int J Periodontics Restorative Dent* 9: 332-343.
17. Bassetti RG, Stähli A, Bassetti MA and Sculean A. Soft tissue augmentation procedures at second-stage surgery: A systematic review (2016) *Clin Oral Investig* 20: 1369-1387. <https://doi.org/10.1007/s00784-016-1815-2>